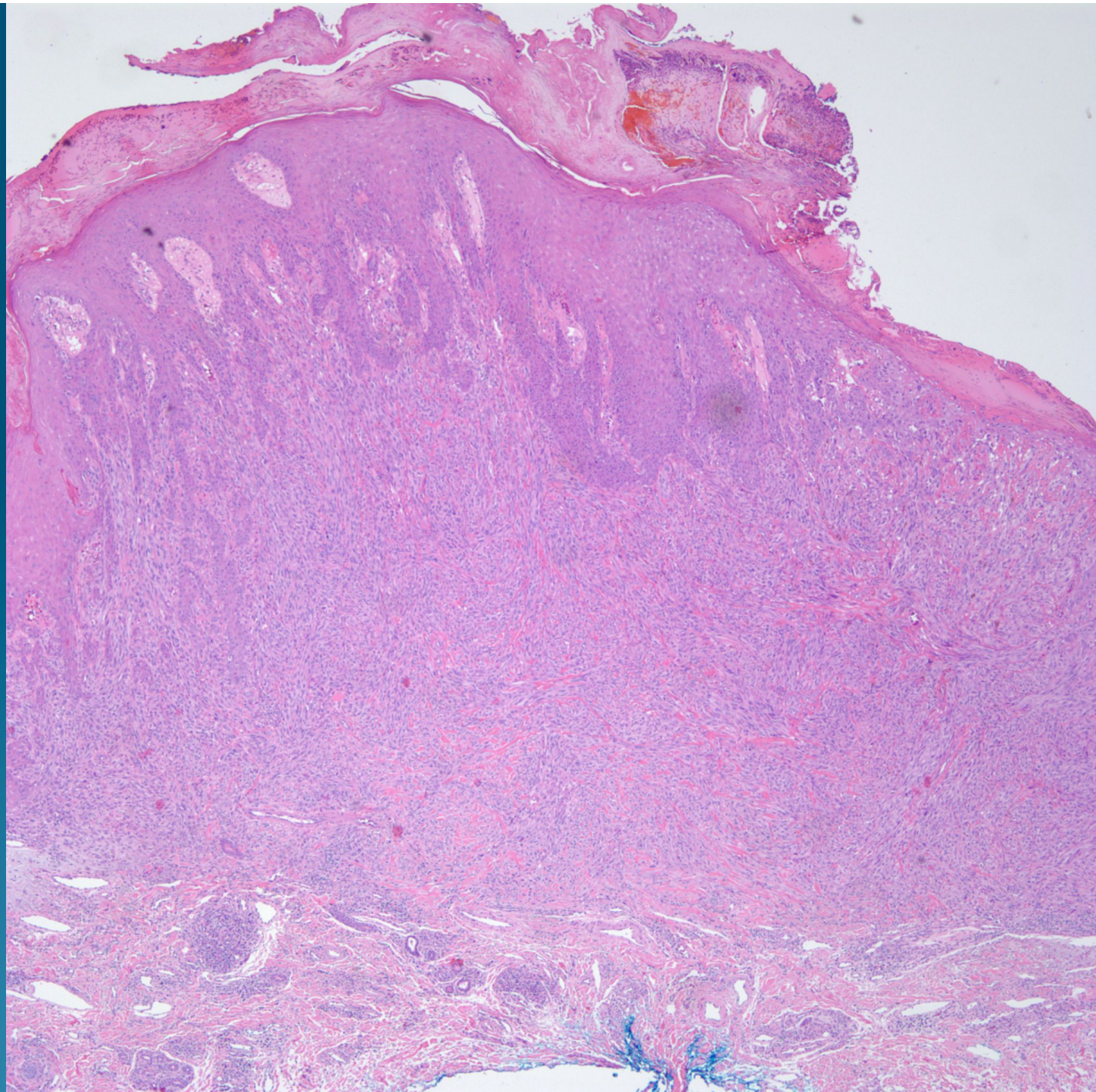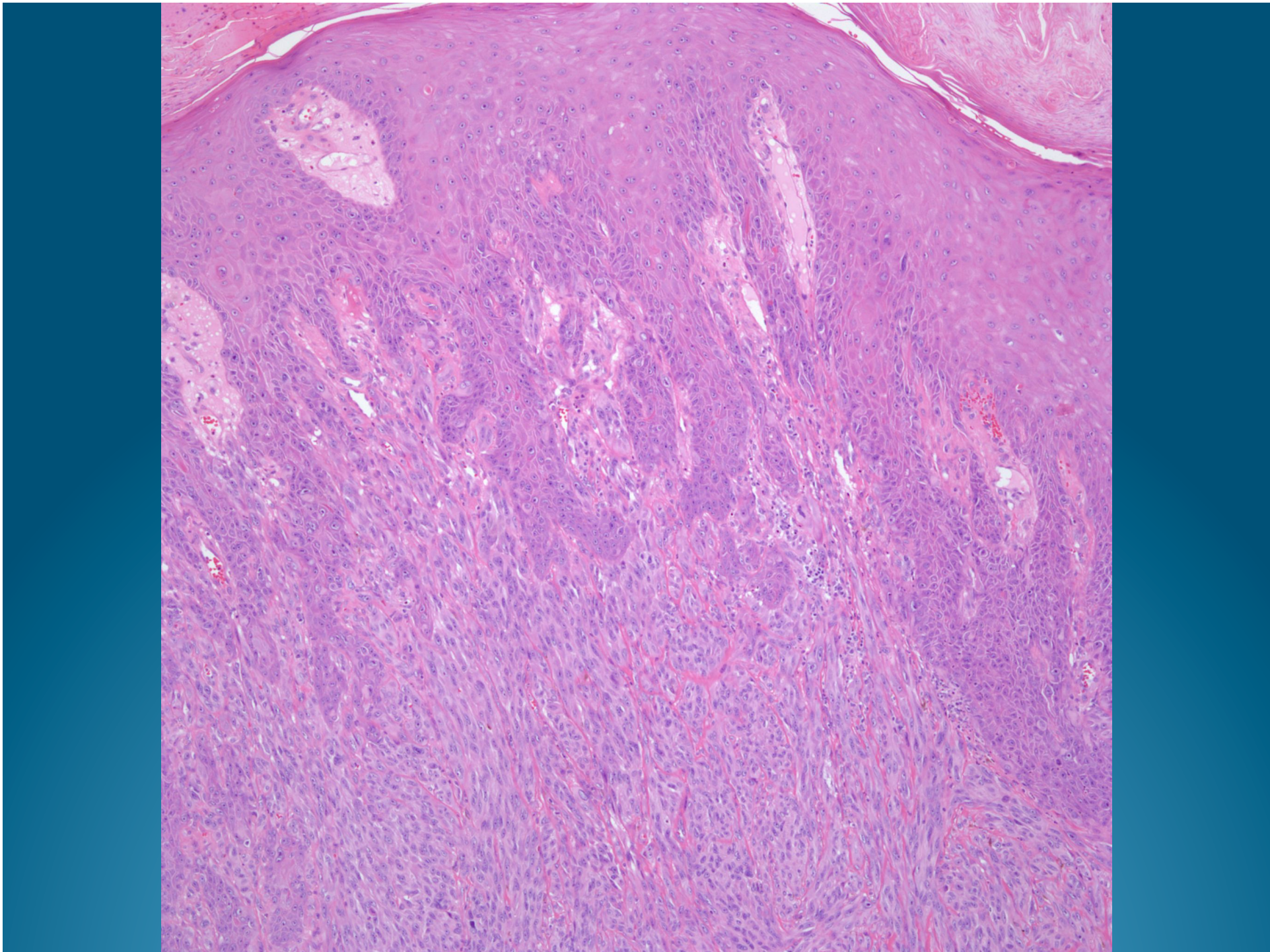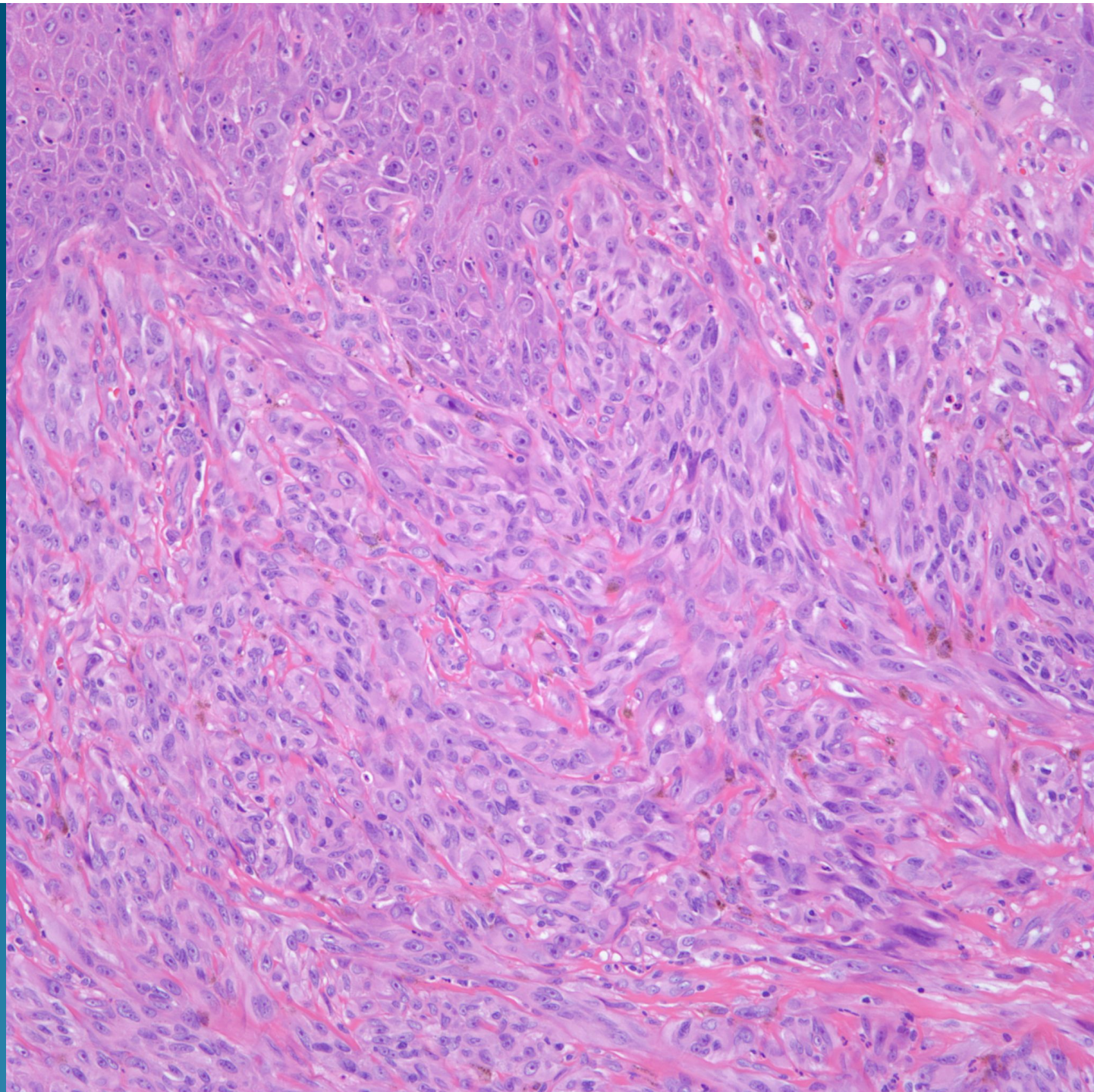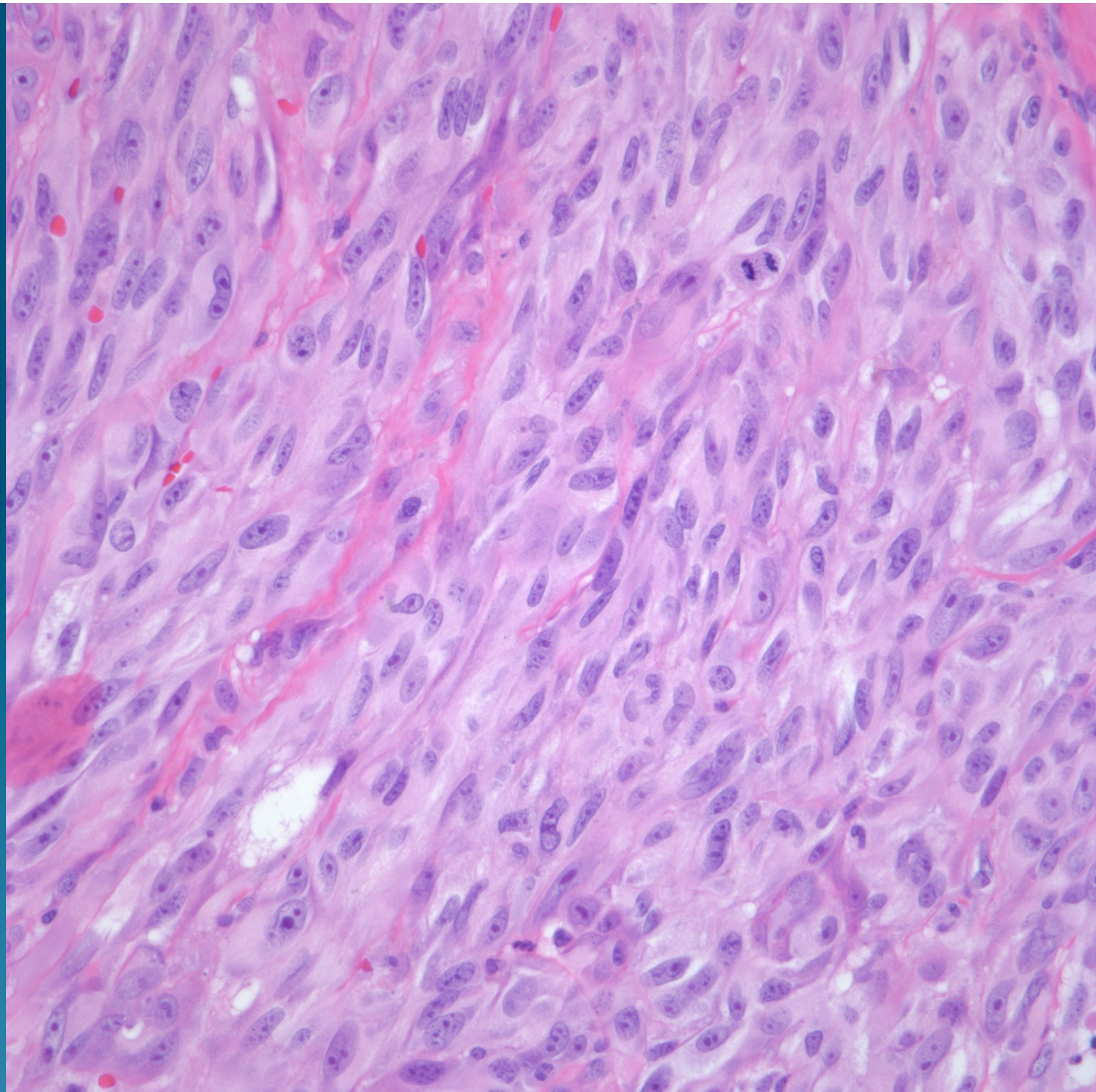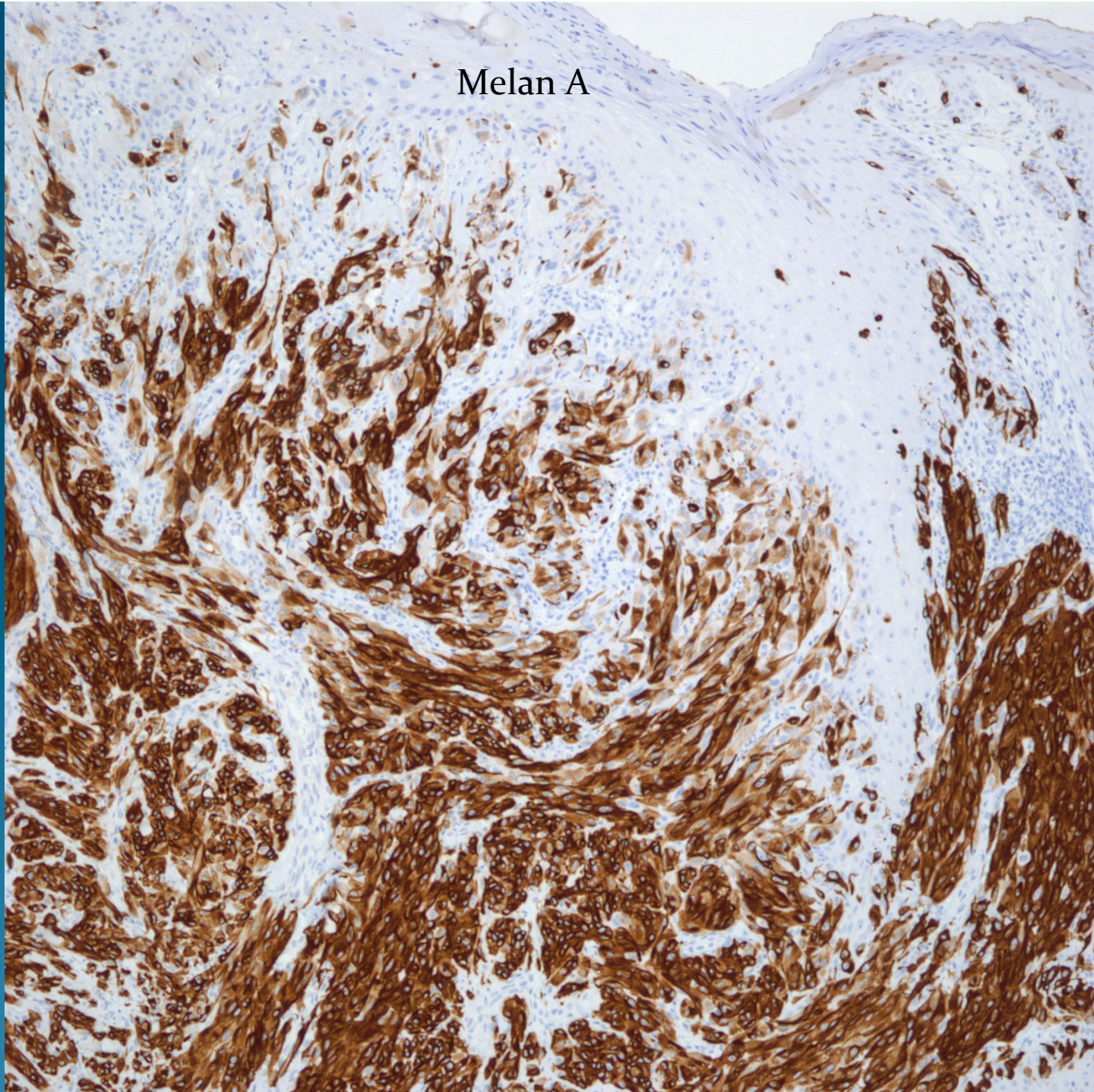
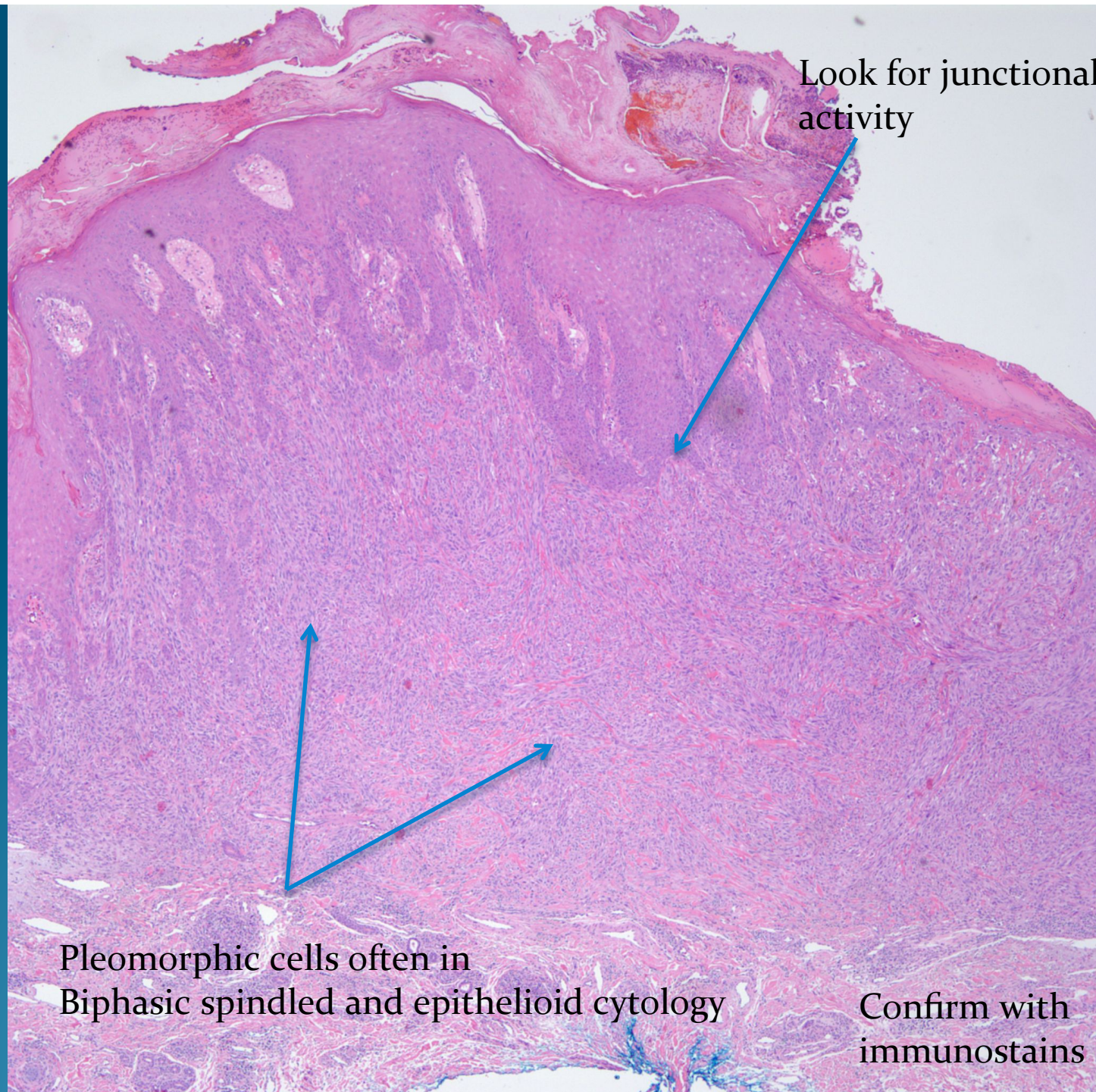


Melan A



Amelanotic Malignant Melanoma



Look for junctional activity

Pleomorphic cells often in
Biphasic spindled and epithelioid cytology

Confirm with
immunostains